

Ketamine Associated Ulcerative Cystitis

Yung-Hsiang Hsu, M.D.*

Department of Pathology, Buddhist Tzu Chi University and Tzu Chi General Hospital, Hualien, Taiwan

*Correspondence: Department of Pathology, Tzu Chi General Hospital, 707 Chung-Yang Road, Section 3, Hualien, Taiwan
E-mail: yhhsu@mail.tcu.edu.tw

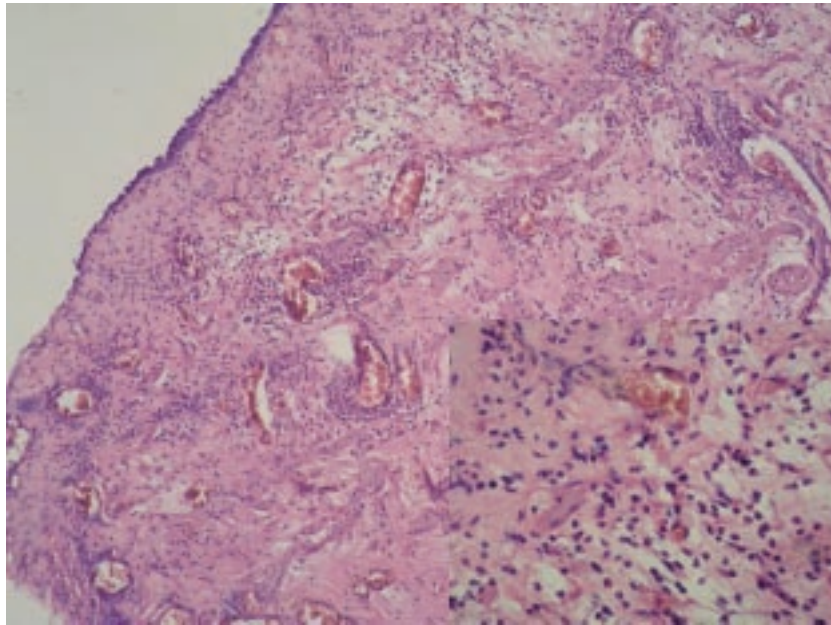


Fig. 1. Histopathology showing denuded urothelial mucosa with a thin layer of reactive and regenerative epithelial cells and ulcerations with vascular granulation tissue and scattered inflammatory cells (Hematoxylin-eosin stain $\times 100$). High power view with hematoxylin-eosin stain showing stromal eosinophils with scattered lymphocytes and mast cells ($\times 400$, right lower panel).

Ketamine hydrochloride is an *N*-methyl-D-aspartic acid receptor antagonist used as an anesthetic agent in humans. Increasingly, it is being used as a recreational drug. Recreational ketamine users have anecdotally reported increased lower urinary tract symptoms while using the substance with symptoms such as severe dysuria, frequency, urgency, and gross hematuria. Their urine cultures are sterile. Computed tomography in these patients reveals marked thickening of the bladder wall, a small capacity, and perivesicular stranding, consistent with severe inflammation. The mechanism by which ketamine induces ulcerative cystitis is not clear. However, it may result from the formation of an active metabolite of ketamine. It is plausible that ketamine and its active metabolites can accumulate in the urine and induce significant bladder irritation. Cystoscopy in these patients shows severe ulcerative cystitis. Biopsies reveal epithelial denudation and inflamma-

tion with mild eosinophilic infiltration (Fig. 1). Cessation of ketamine use, and administration of pentosan polysulfate appear to provide some symptomatic relief.

FURTHER READINGS

1. Chiew YW, Yang CS: Disabling frequent urination in a young adult. Ketamine-associated ulcerative cystitis. *Kidney Int* 2009; **76**:123-124.
2. Tsai JH, Tsai KB, Jang MY: Ulcerative cystitis associated with ketamine. *Am J Addict* 2008; **17**:453.
3. Shahani R, Streutker C, Dickson B, Stewart RJ: Ketamine-associated ulcerative cystitis: A new clinical entity. *Urology* 2007; **69**:810-812.